



PATIENT PRESENTING CLINICAL SIGNS

Isabel Medina Nasal discharge. O stated P gets build of phlegm in nose for a few weeks (3-4 weeks). Bilateral cloudy nasal discharge

SPECIES

Canine

COMPUTED TOMOGRAPHIC STUDY OF THE HEAD

Plain study only available for review.

BREED

Pug

COMPUTED TOMOGRAPHIC FINDINGS

Bilateral mucosal thickening of the nasal cavities accentuating the ventral nasal passages is seen. Fluid / mucus accumulating within the nasal cavities, no discrete masses identified.

SEX

There is no evidence of foreign material or destructive changes of the nasal bones or ethmoid region.

FS

There are no frontal sinuses as common in brachiocephalic dogs.

AGE

11

Teeth 105 through 110 are absent. Teeth 201 and 207 show severe periodontitis with periodontal space widening and root resorption, extensive dental plaques of the maxillary molar teeth are seen.

The tympanic bullae and skull bones are within normal limits.

INTERPRETED BY

Nele Eley (Ondreka),
DVM Dr. med. vet.,
DipECVDI

COMPUTED TOMOGRAPHIC DIAGNOSIS

- Chronic bilateral rhinitis with mucus accumulation.
- Dental disease: periodontitis and root resorption 201 and 207 may be a contributing factor
- No mass or destructive lesions identified

HOSPITAL NAME

Scottsdale Veterinary
Clinic

INTERPRETATION OF FINDINGS & FURTHER RECOMMENDATIONS

The CT study reveals evidence of chronic bilateral non-destructive rhinitis with mucus accumulation. The dental disease may contribute to the rhinitis. However, currently no destructive or invasive dental nasal involvement is noted. No mass or destructive lesions identified. Malignancy is considered unlikely.

REFERRING VET

Dr Gans

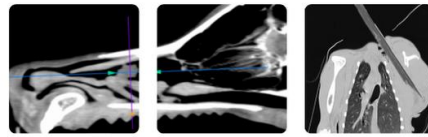
Consider addressing the dental disease with treatment of 201 and 207 and medical management of rhinitis. Optional endoscopy with sampling can be considered as well.

INVOICE

23832

DATE

02/16/2026



PATIENT

Isabel Medina

SPECIES

Canine

BREED

Pug

SEX

FS

AGE

11

INTERPRETED BY

Nele Eley (Ondreka),
DVM Dr. med. vet.,
DipECVDI

HOSPITAL NAME

Scottsdale Veterinary
Clinic

REFERRING VET

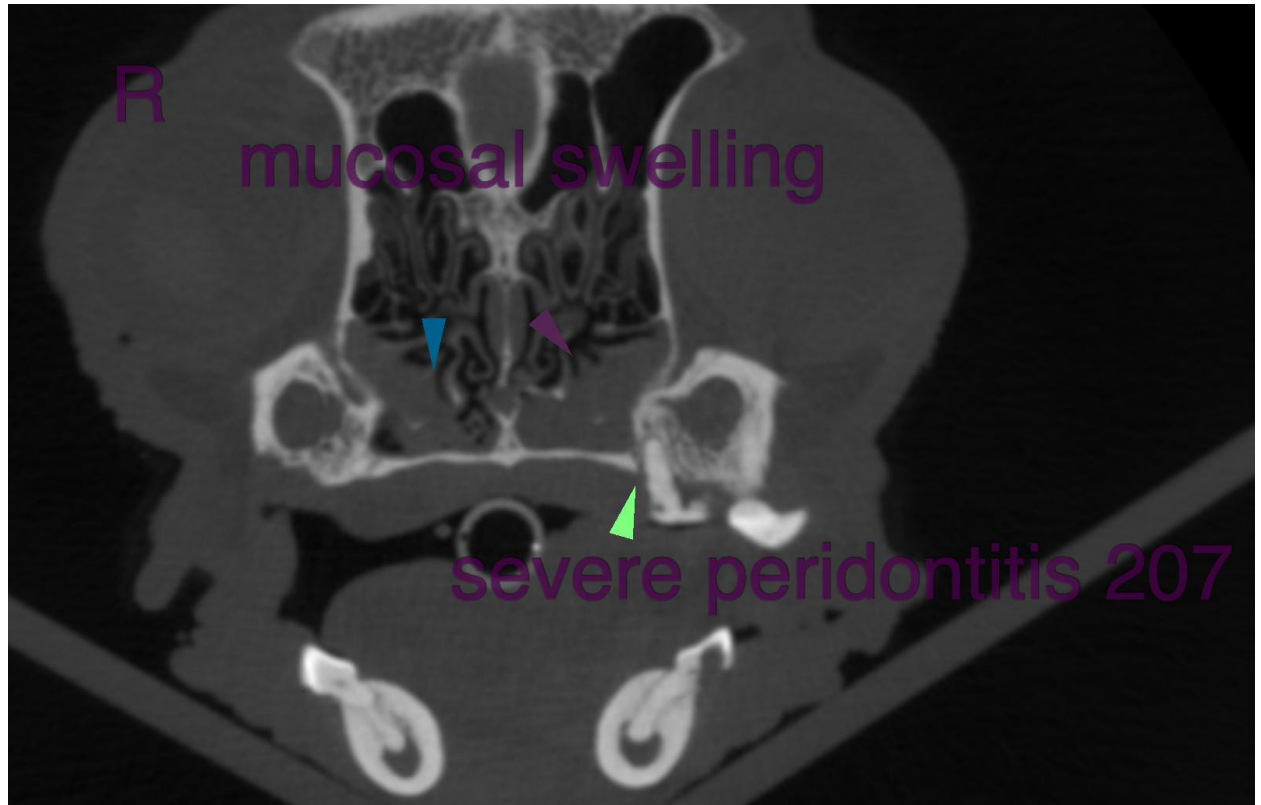
Dr Gans

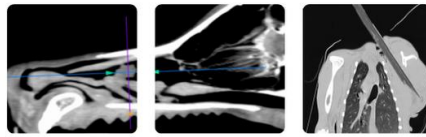
INVOICE

23832

DATE

02/16/2026





PATIENT

Isabel Medina **The information and recommendations provided are based on the images presented by the referring veterinarian. No evaluation can be communicated regarding pathology that was not visible in the image/video clips provided.**

SPECIES

Canine Thank you for this referral. If the clinical or image interpretation does not parallel your findings or if I can be of any further assistance please contact me.

BREED

Pug **Nele Eley (Ondreka), DVM, Dr. med. vet., DipECVDI**
European Specialist in Veterinary Diagnostic Imaging, Cert. Radiology,
Senior lecturer University of Giessen/Germany, Veterinary Faculty, Department of Radiology.
info@sonopath.com

SEX

FS

AGE

11

INTERPRETED BY

Nele Eley (Ondreka),
DVM Dr. med. vet.,
DipECVDI

HOSPITAL NAME

Scottsdale Veterinary
Clinic

REFERRING VET

Dr Gans

INVOICE

23832

DATE

02/16/2026